The International Journal of Indian Psychology
ISSN 2348-5396 (Online) | ISSN: 2349-3429 (Print)
Volume 9, Issue 4, October- December, 2021
DIP: 18.01.084.20210904, DOI: 10.25215/0904.084
http://www.ijip.in

Research Paper

An Approach to Understand Epilepsy and The Role of EEG in Its Diagnosis

Pratima Singh[1]*

ABSTRACT

Epilepsy is one of the most prevalent and debilitating neurological diseases yet there is a limited understanding of its psychophysiology and because of which its detection as well as treatment is delayed. The present article reviews the neurology and psychophysiology behind epilepsy and epileptic seizure and the role of electroencephalography (EEG) in the diagnosis of the same. The advantages and disadvantages of electroencephalography (EEG) in the diagnosis are discussed in length in this paper. The major drawback in the treatment or field of epilepsy is the criticality of the early detection of epilepsy and epileptic seizure. The article highlights the need of developing automated diagnostic system for epilepsy and seizure detection for patients as well as clinicians.

Keywords: *Epilepsy, Epileptic Seizure, Electroencephalography*

What is Electroencephalography (EEG)?

Hans Berger (1929) discovered EEG as a non-invasive measure for functional imaging of the brain. EEG is a tool that records the electrical activity in the brain. There are lacks of neurons inside the neural structure of the brain. These neurons interact by colliding and transferring information to each other and because of this collision a very small magnitude of electricity is generated. An individual's behaviour is determined by this electrical flow of signals. These signals fluctuate depending upon individual's daily behaviour. Different human behaviour forms different oscillatory frequencies. A normal flow of electrical signals in the human brain determines a healthy functioning of the brain and irregular or unbalanced flow of electrical signals leads to an unhealthy human brain. Therefore, EEG could help in locating and recording this unusual flow of electric currents inside the human brain. This recording of electrical activity is performed by placing electrodes on the human scalp that records the electrical fluctuations in the brain for a brief amount of time. EEG provides a better temporal resolution but a lower spatial insight.

There are several clinical applications of EEG in humans and animals (Bickford et al., 1972) such as monitoring of consciousness, coma or brain death in patients, monitoring of cognitive engagement, providing biofeedback, locating impaired brain regions after head

[1]Research Scholar, University of Delhi, New Delhi, India
*Corresponding Author

Received: October 05, 2021; Revision Received: November 04, 2021; Accepted: November 27, 2021

injury, brain stoke or trauma, diagnosis of epilepsy or epileptic seizure and investigation of sleep disorders and its physiology.

EEG typically consists of five brain oscillations, a summary of frequency bands and their function is presented in a table below-

Brain Oscillations	Frequency range (in Hz)	Functions
Gamma	30- Above	Fastest waves and associated with high level of arousal
Beta	13-30	Associated with normal working state or less active state
Alpha	8-13	Most prominent during relaxed state or eyes closed
Theta	4-7	During sleep and drowsy state
Delta	1-4	Associated with deep mediation or sleep

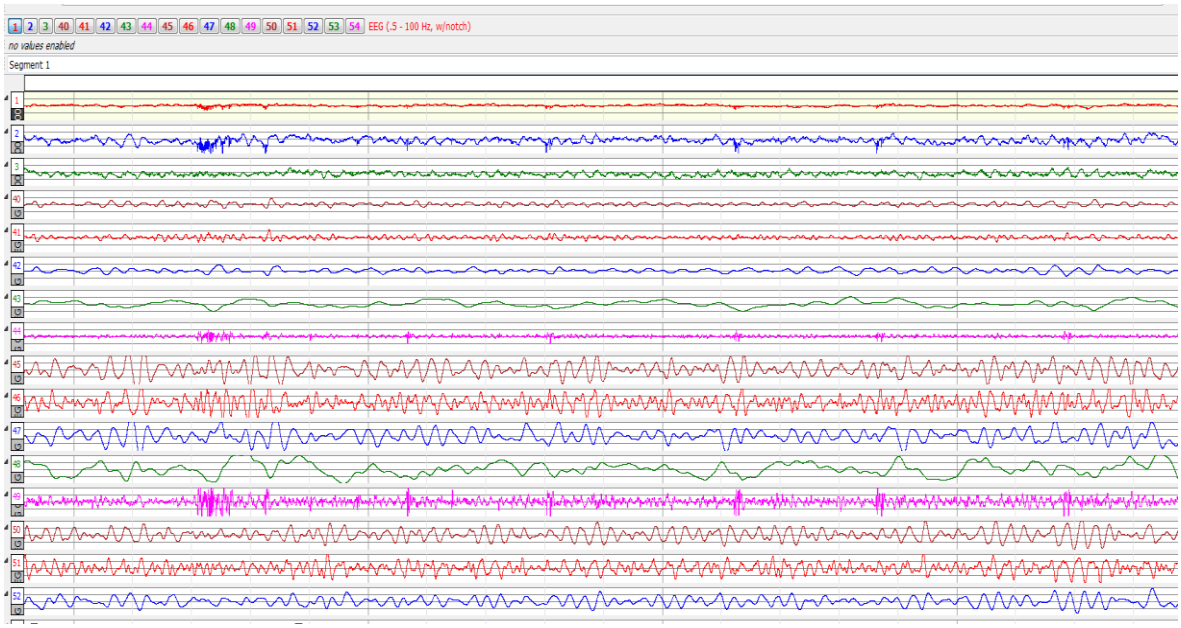

Fig. 1. The raw EEG recording of a baseline sample of a healthy human brain.

Understanding Epilepsy and Epileptic Seizure

A neurological disorder can develop in the human brain as a result of abnormal or irregular neural activity. A seizure is a sudden outburst in neural functioning generated by brain's excessive and hyper-synchronic firing of neurons. It is defined as a 'distortion between the balance of excitatory and inhibitory neuronal firing' (Stafstrom, 2010). The condition of recurring unprovoked seizures is known as epilepsy. In epilepsy, the usual patterns of brain activity get disrupted, leading to unusual sensation, mood swings, abnormal behaviours, muscular spasm and convulsions (Yuedong., 2011). Epileptic seizure refers to seizure induced by aberrant neuronal activity. Typically lasting for only a few minutes, it is triggered by a sudden self-sustaining, irregular electrical currents in the cerebral cortex. These seizures can disrupt movements, bowel functioning, cognitive processes or lead to unconsciousness. The characteristics of a seizure are determined by three important factors- its spread, the degree of electrical discharge generated by irregular neuronal firing and the particular affected brain region.

International Bureau for Epilepsy (IBE) and International League Against Epilepsy (ILAE) defined epilepsy as a neurological condition categorized by recurrent unprovoked convulsion due to irregular electrical activity inside the brain (Guo et al., 2012). WHO (2013) reported that globally 50 million people suffer from epilepsy. Epileptic seizures are difficult to predict therefore, early detection of epilepsy is critical for avoiding and mitigating their negative consequences. There are four stages of epileptic seizure-

1. **Pre-ictal State-** A pre-ictal state appears over a certain time period before the onset of a seizure and generally does not occur at other times. It might be difficult to identify it by simply looking at it. It will, however, indicate changes in the brain signals inside the brain which would predict the seizure within a certain range of values.
2. **Pro-ictal State**- Seizures are more common in this condition, though not guaranteed.
3. **Ictal and Interictal State**- In the ictal state, a change in the EEG signal occurs during epileptic seizure while the interictal state is the period between two subsequent seizures onsets.
4. **Post ictal State**- This state marks the closure of epileptic seizure.

To be clinically useful, a pre-ictal condition must be recognized early so that the time spent under false alarm is reduced (Kuhlmann et al., 2018). The pattern that neural oscillations form may include significant information regarding the functioning of the brain. By observing the EEG oscillations, experienced neurologists can make a diagnosis about neuronal disorders.

Diagnosis of epilepsy through EEG

EEG is useful and reliable tool for diagnosis of functional anatomy of the brain during epilepsy or epileptic seizure. The irregular flow of EEG signals leads to a neurological conditions including epilepsy. Hence, such irregularities should be thoroughly examined in order to define the pattern of epilepsy which maybe be generalized for predicting the onset of it in human brains.

With the analysis of EEG recordings, normal and abnormal brain activity could be segregated. Longer duration EEG recordings are essential for an accurate prediction of epilepsy. Initial recording of EEG may seem normal in 12-50 percent of epileptic patients (van Doselaar et al., 1992; Goodin et al., 1990), on the other hand, repeated EEG enhances diagnostic accuracy (Salinsky et al., 1987).

The speed and preciseness of EEG is its most significant advantage. It can record even the minute impulse inside the EEG signal in a matter of minutes or even seconds. The examination of continuous EEG recordings are monitored by expert neurologists for a longer period of time close to weeks or months which necessitate a significant amount of effort and patience. However due to the increased temporal and spatial resolution, this process becomes time consuming and vulnerable to faulty erroneous detection. Therefore, computerized methods for extracting and analyzing EEG signals could be remarkably useful for diagnosis.

Routine EEG is essential in order to make a diagnosis of epilepsy, to segregate epileptic EEG signals from non-epileptic ones and to come up with the patterns that generates during epilepsy or epileptic seizures for the purpose of understanding and prediction. Even after taking plenty of precautions, patients have seizures and then the EEG signals are constantly recorded.

Relevance of Automated Seizure Detection EEG Algorithm

There are several reasons why neurologists want seizures to be diagnosed using EEG. Early detection of seizure is a crucial part for its treatment. Through the continuous monitoring of EEG signals, it is essential to detect it so that it's spread could be monitored also, and at times a radiation dye injection is given when the seizure starts. The detection of seizure is also essential for making the appropriate kind of treatment decision e.g., medication, electrical stimulation etc.

There can be different manifestations of a seizure. The characteristics of neural oscillations are most often detected in the EEG for seizure detection. During seizure EEG signals can become more oscillatory in comparison to regular activity, different channels may respond similarly like one another and the amplitude becomes longer during a seizure than it was before it. It is essential to note down that even after these features, it is very difficult to predict a seizure as each seizure may be different from other and may or may not display any or all of these features. Many non-epileptic events such as artefacts (sneeze, muscle movement, cough etc) also exhibit the similar characteristics as seizure. In a study, when four expert neurologists were asked to evaluate the same EEG recording that had previously marked separately by another expert, only ninety percent of the occurrences were the same detected ones by another expert, and overall, less than 80 percent of the events were marked by two or more experts (Williams et al., 1995). Therefore, designing a detector to identify a target that is distinct from background activity but is not an artefact is the key for epilepsy or epileptic seizure detection. However, identifying a single characteristics or combination of features capable of distinguishing between seizure and non-seizure EEG signals is challenging. Therefore, for an efficient and quick diagnosis of epilepsy and seizure an automated detection tool is essential which might serve as important tool for evaluation of complex EEG signals.

CONCLUSION

The present review illustrates the understanding of epilepsy and epileptic seizure. Further, the role of EEG is one of the most significant measures for epilepsy diagnosis. It allows the simple monitoring and management of several neurological conditions. Yet, manual inspection of EEG signals for long duration is time- consuming, tiring process which may provide sometimes inefficient and delayed information and also disagreement among neurologists because of subjective nature of diagnosis. Therefore, an automated detection tool is needed because if EEG signal are monitored properly and specific features are extracted correctly it may lead to a better diagnosis and save the patient from further harm.

REFERENCES

Bickford, R. G. (1972). Values and Limitations of EEG monitoring in Intensive- Care Units. *Electroencephalography and Clinical Neurophysiology*, 32(1), 101.

Goodin, D. S., Aminoff, M. J., & Laxer, K. D. (1990). Detection of epileptiform activity by different noninvasive EEG methods in complex partial epilepsy. *Annals of Neurology: Official Journal of the American Neurological Association and the Child Neurology Society*, *27*(3), 330-334.

Guo, W., Wu, J., Wang, W., Guan, B., Snape, D., Baker, G. A., & Jacoby, A. (2012). The stigma of people with epilepsy is demonstrated at the internalized, interpersonal and institutional levels in a specific sociocultural context: findings from an ethnographic study in rural China. *Epilepsy & Behavior*, *25*(2), 282-288.

Kuhlmann, Levin, Klaus Lehnertz, Mark P. Richardson, Björn Schelter, and Hitten P. Zaveri. "Seizure prediction—ready for a new era." *Nature Reviews Neurology* 14, no. 10 (2018): 618-630.

Salinsky, M., Kanter, R., & Dasheiff, R. M. (1987). Effectiveness of multiple EEGs in supporting the diagnosis of epilepsy: an operational curve. *Epilepsia*, *28*(4), 331-334.

Stafstrom, C. E. (2010). Pathophysiological mechanisms of seizures and epilepsy: a primer. *Epilepsy: mechanisms, models, and translational perspectives*, 3-19.

van Donselaar, C. A., Schimsheimer, R. J., Geerts, A. T., & Declerck, A. C. (1992). Value of the electroencephalogram in adult patients with untreated idiopathic first seizures. *Archives of neurology*, *49*(3), 231-237.

Williams, J., Sharp, G. B., Griebel, M. L., Knabe, M. D., Spence, G. T., Weinberger, N., ... & Rickert, V. (1995). Outcome findings from a multidisciplinary clinic for children with epilepsy. *Children's Health Care*, *24*(4), 235-244.

Yuedong S. 2011. A Review of Developments of EEG- Based Automatic Medical Support System for Epilepsy Diagnosis and Seizure Detection. J. Biomed Sci Eng. 4:788–796.

Acknowledgement

The author(s) appreciates all those who participated in the study and helped to facilitate the research process.

Conflict of Interest

The author(s) declared no conflict of interest.

How to cite this article: Singh P. (2021). An Approach to Understand Epilepsy and The Role of EEG in Its Diagnosis. *International Journal of Indian Psychology*, *9*(4), 858-862. DIP:18.01.084.20210904, DOI:10.25215/0904.084